

Investigating Biological Activity Potential of *Plantago lanceolata* L. in Healing of Skin Wounds by a Preclinical Research

Esin KURANEL¹, Esra KÜPELİ AKKOL^{2*}, Ipek SÜNTAR², Şule GÜRSOY¹, Hikmet KELEŞ³, Gökür AKTAY¹

¹Inönü University, Faculty of Pharmacy, Department of Pharmacology, 44280 Malatya, TURKEY, ²Gazi University, Faculty of Pharmacy, Department of Pharmacognosy, Etiler 06330 Ankara, TURKEY, ³Afyon Kocatepe University, Faculty of Veterinary Medicine, Department of Pathology, 03200 Afyonkarahisar, TURKEY

Plantago lanceolata L. has been used for wound healing in Turkish traditional medicine. In the present study the wound healing and anti-inflammatory effects of the aqueous and methanol extract of *P. lanceolata* were investigated. *In vivo* excision and incision wound models were applied on mice and rats for the evaluation of the wound healing effect of *P. lanceolata*. Inhibitory effect of the extracts on acetic acid-induced increase in capillary permeability was assessed by using Whittle Method. Moreover, the levels of thiobarbituric acid reactive substances (TBARs), glutathione (GSH), total thiols (TSH), hydroxyproline (HP), and tissue trace elements (Zn⁺² and Cu⁺²) were analysed. The aqueous extract of *P. lanceolata* was found to have wound healing activity in both incision and excision wound models. The results obtained from histopathological analysis also supported the data. Significant anti-inflammatory activity was also detected for both extracts. *P. lanceolata* significantly reduced the levels of TBARs which is one of the indicators of oxidative stress on the wounded tissue and increased the levels of GSH, TSH and HP. Additionally, *P. lanceolata* was found to have capacity to increase the levels of tissue Zn⁺² and Cu⁺², both of which are important indicators in the process of wound healing and collagen synthesis. The results indicated that *P. lanceolata* which is used in the treatment of wounds in addition to many illnesses in traditional medicine and is rich in terms of flavanoids has a powerful antioxidant effect and so it has a positive assistance in healing process. More advanced studies are needed to illuminate the mechanism accurately.

Key words: Glutathione, *Plantago lanceolata*, Plantaginaceae, Thiobarbituric acid, Wound healing

Plantago lanceolata L.'nin Deri Yaralarını İyileştirici Etkisinin Preklinik Araştırma ile Değerlendirilmesi

Plantago lanceolata L. bitkisi, Türk Halk Tıbbında yara iyileştirici amaçla kullanılmaktadır. Bu çalışmada, *P. lanceolata*'nın sulu ve metanollü ekstralarının yara iyileştirici ve anti-enflamatuvar etkilerinin araştırılması amaçlanmıştır. Bitkinin yara iyileştirici etkisinin değerlendirilmesi için fare ve sıçanlarda *in vivo* eksizyon ve insizyon yara modelleri kullanılmıştır. Ekstrelerin asetik asit-nedenli kapiller permeabilite artışını inhibe edici etkileri Whittle Yöntemi kullanılarak araştırılmıştır. Bununla beraber, dokulardaki tiyobarbitürik asit reaktifleri (TBARs), glutatyon (GSH), total tiyol grupları (TSH) ve hidroksiprolin (HP) seviyeleri ile iz elementlerin (Zn⁺² ve Cu⁺²) miktarları analiz edilmiştir. *P. lanceolata*'nın sulu ekstrelerinin insizyon ve eksizyon yara modellerinde yara iyileştirici etkiye sahip olduğu tespit edilmiştir. Histopatolojik incelemeler sonucunda elde edilen veriler de bu sonuçları desteklemektedir. Bitkinin her iki ekstrelerinin de anlamlı derecede anti-enflamatuvar etkiye sahip olduğu belirlenmiştir. *P. lanceolata*'nın oksidatif stresin bir göstergesi olan TBARs seviyesini anlamlı derecede düşürdüğü, diğer taraftan, GSH, TSH ve HP seviyelerini arttırdığı tespit edilmiştir. Buna ek olarak, bitkinin, yara iyileşmesi ve kolajen sentezi sürecinde önemli rolleri olan Zn⁺² ve Cu⁺² seviyelerinde artış sağladığı belirlenmiştir. Sonuçlar, Türkiye'de halk arasında yara iyileştirici amaçla kullanılan, flavonoit içeriği bakımından zengin ve antioksidan etkisiyle bilinen *P. lanceolata*'nın yara iyileşmesi sürecinde etkili olduğunu göstermiştir. Bitki üzerinde, etki mekanizmasının aydınlatılmasına yönelik ileri çalışmalara ihtiyaç duyulmaktadır.

Anahtar kelimeler: Glutatyon, *Plantago lanceolata*, Plantaginaceae, Tiyobarbitürik asit, Yara iyileşmesi

*Correspondence: E-mail: esrak@gazi.edu.tr; Tel: +90 312 2023185

INTRODUCTION

Plants have been used for the treatment of various ailments since ancient times. Especially in rural areas these formulations are considered to be essential for the human health (1). Traditional remedies for wound healing also have a wide usage among the people living in the rural areas. Several medicinal plants have been reported to be used for the treatment of wounds and ulcers (2). Among these plants, *Plantago* species were reported to be used as wound healing agent with its astringent, haemostatic and antimicrobial properties. Especially, *Plantago major* L. and *Plantago lanceolata* L. are the widespread species among the 26 taxa growing in Turkey. Previous studies have shown that *Plantago* species have analgesic, anti-inflammatory, antimicrobial, antioxidant, antispasmodic, hepatoprotective activities, and cytotoxic effect on the cancer cells (3-5). More specifically, the aerial parts of *P. lanceolata* have been reported to possess anti-inflammatory, antibacterial, diuretic, antiasthmatic and wound healing potential (6,7).

In the present study, the possible wound healing potential of *P. lanceolata* from family Plantaginaceae, was assessed by using linear incision and circular excision wound models. Furthermore, hydroxyproline levels of the tissue samples were investigated. In the wound healing process, superoxide and hydroxyl radicals could increase lipid peroxidation and therefore, cause cell and tissue damage (8). Particularly in the phase of haemostasis, oxidative stress plays an important role and preventing this oxidative damage is essential for the healing process. Hence, the antioxidant effect of the extracts from *P. lanceolata* was evaluated by measuring the levels of thiobarbituric acid reactive substances (TBARs), glutathione (GSH), total thiols (TSH), hydroxyproline (HP) and tissue trace elements (Zn^{+2} and Cu^{+2}) in the present study.

EXPERIMENTAL

Plant material

P. lanceolata was collected from the campus of İnönü University, Malatya in June, 2011 and identified by N. Sadıkoğlu. The voucher

specimen (INUE-1328) is deposited in the herbarium of the Faculty of Pharmacy, İnönü University, Malatya.

Preparation of the plant extract

Dried *P. lanceolata* leaves (60 g) were powdered and extracted with 1500 mL distilled water and 1500 mL methanol separately at room temperature for 48 h. The extracts were filtered and evaporated to dryness under vacuum at 47°C by using a rotary evaporator. The aqueous extract was lyophilized.

Pharmacological Procedures

Animals

Male Sprague–Dawley rats (160–180 g) and Swiss albino mice (20–25 g) were obtained from the animal breeding laboratory of Saki Yenilli (Ankara, Turkey). The animals were left for 3 days for acclimatization into animal room conditions and were maintained on standard pellet diet and water *ad libitum*. For the anti-inflammatory activity assessment the food was withdrawn on the day before the experiment, but free access to water was allowed. Six animals were used in each group for the experiments. The present study was performed according to the international rules considering the animal experiments and biodiversity rights (G.U.ET-08.037).

Preparation of test samples for bioassay

Test samples were given orally to the animals after suspending in a mixture of distilled water and 0.5% sodium carboxymethyl cellulose (CMC) for the anti-inflammatory activity assessment. The control group animals received the same experimental handling as those of the test groups except that the drug treatment was replaced with appropriate volumes of the dosing vehicle. Indomethacin (10 mg/kg) in 0.5% CMC was used as a reference drug.

For the assessment of wound-healing activity the test ointments were prepared by mixing the extracts with a mixture of ointment base consisting of glycol stearate: propylene glycol and liquid paraffin (3:6:1) in a mortar thoroughly. Treatments were started immediately after the production of wound by daily application of the test ointments on the wounded area. The control group animals were topically treated with ointment base, while the

animals in negative control group were not treated with any product. Madecassol[®] (Bayer) (0.5 g) was used topically as the reference drug (9).

Wound Healing Activity

Linear incision wound model

Animals were anesthetized with 0.05 cc Xylazine (2% Alfazine[®]) and 0.15 cc Ketamine (10% Ketazol[®]) and the back hair of the rats were shaved and cleaned with 70% alcohol. Two 5 cm-length linear-paravertebral incisions were created with a sterile blade at the distance of 1.5 cm from the dorsal midline on each side. Three surgical sutures were placed each 1 cm apart.

The test ointments, the reference drug (Madecassol[®]) and ointment base were topically applied on the dorsal wounds in each group of animals once daily throughout 9 days. All the sutures were removed on the last day and tensile strength of previously wounded and treated skin was measured by using a tensiometer (Zwick/Roell Z0.5, Germany) (9-11).

Circular excision wound model

This model was used to monitor wound contraction and wound closure time. Each group of animals was anesthetized with 0.02 cc Xylazine (2% Alfazine[®]) and 0.08 cc Ketamine (10% Ketazol[®]). The back hairs of the mice were depilated by shaving. The circular wound was created on the dorsal interscapular region of each animal by excising the skin with a 5 mm biopsy punch (Nopa instruments, Germany); wounds were left open. Test samples, the reference drug (Madecassol[®], Bayer) and the vehicle ointments were applied topically once a day till the wounds completely healed. The progressive changes in wound areas were monitored by a camera (Fuji, S20 Pro, Japan) every other day. Wound areas were evaluated by using AutoCAD program. Wound contraction was calculated as percentage of the reduction in wounded area. A specimen sample of tissue was isolated from the healed skin of each group of mice for the histopathological analysis (12).

Histopathology

The tissue specimens were fixed in 10% buffered formalin, processed and blocked with paraffin and then sectioned into 5 micrometer sections and stained with hematoxylin & eosin

(HE) and Van Gieson (VG) stains. The tissues were examined by light microscope (Nikon Eclipse Ci attached Kameram[®] Digital Image Analyze System) and graded as mild (+), moderate (++) and severe (+++). Re-epithelization or ulcer in epidermis; fibroblast proliferation, mononuclear and/or polymorphonuclear cells, neovascularization and collagen depositions in dermis were analyzed to score the epidermal or dermal re-modeling (13).

Hydroxyproline estimation

Tissues were dried in hot air oven at 60-70°C until consistent weight was achieved. Samples were hydrolyzed with 6 N HCl for 3 hours at 130°C, were adjusted to pH 7 and subjected to chloramin T oxidation. The colored adduct formed with Ehrlich reagent at 60°C was measured at 557 nm. Standard hydroxyproline was also run and values reported as µg/mg dry weight of tissue (13, 14).

Anti-inflammatory Activity

Acetic acid-induced increase in capillary permeability

Effect of the test samples on the increased vascular permeability induced by acetic acid in mice was determined according to Whittle method with some modifications (15, 16). Each test sample was administered orally to a group of 10 mice in 0.2 mL/20 g body weight. Thirty minutes after the administration, tail of each animal was injected with 0.1 mL of 4% Evans blue in saline solution (i.v.) and waited for 10 min. Then, 0.4 mL of 0.5% (v/v) AcOH was injected *i.p.* After 20 min. incubation, the mice were killed by dislocation of the neck, and the viscera were exposed and irrigated with distilled water, which was then poured into 10 mL volumetric flasks through glass wool. Each flask was made up to 10 mL with distilled water, 0.1 mL of 0.1N NaOH solution was added to the flask, and the absorption of the final solution was measured at 590 nm (Beckmann Dual Spectrometer; Beckman, Fullerton, CA, USA). A mixture of distilled water and 0.5% CMC was given orally to control animals, and they were treated in the same manner as described above.

Lipid peroxidation (TBARS)

The method of Ohkawa et al. (1979) as modified by Jamall and Smith (1985) was used to determine lipid peroxidation in tissue samples (17, 18). The wet tissues were homogenized in 9 mL of 0.25 M sucrose using a Teflon homogenizer to obtain a 10% suspension. The cytosolic fraction was obtained by a two step-centrifugation first at 1000 x g for 10 min and then at 2000 x g for 30 min at 4°C. A volume of the homogenate (0.20 mL) was transferred to a vial and was mixed with 0.2 mL of a 8.1% (w/v) sodium dodecyl sulfate solution, 1.50 mL of a 20% acetic acid solution (adjusted to pH 3.5 with NaOH) and 1.50 mL of a 0.8% (w/v) solution of TBA and the final volume was adjusted to 4.0 mL with distilled water. Each vial was tightly capped and heated in a boiling water bath for 60 min. The vials were then cooled under running water.

Equal volumes of tissue blank or test sample and 10% TCA were transferred into a centrifuge tube and centrifuged at 1000 x g for 10 min. The absorbance of the supernatant fraction was measured at 532 nm (Beckman DU 650 Spectrometer). Control experiment was processed using the same experimental procedure except the TBA solution was replaced with distilled water. 1,1,3,3-Tetraethoxypropan was used as standard for calibration of the curve.

T-SH and NP-SH (GSH)

Tissues were homogenized in 0.02 M ethylenediaminetetraacetic acid disodium (EDTA-Na₂). For determination of total-SH groups, aliquots of 0.5 mL of the homogenates were mixed with 1.5 mL of 0.2 M Tris buffer, pH 8.2, and 0.1 mL of Ellman's reagent. The mixture was brought to 10.0 mL with 7.9 mL of absolute methanol. Color was developed for 15 min and the reaction mixtures centrifuged at approximately 3000 x g at room temperature for 15 min. The absorbance of supernatants was read at 412 nm.

For the determination of GSH, aliquots of 5.0 mL of the homogenates were mixed with 4.0 mL distilled water and 1.0 mL of 50% TCA. Tubes were centrifuged for 15 min at approximately 3000 x g. 2.0 mL of supernatant was mixed with 4.0 mL of 0.4 M Tris buffer pH 8.9 and 0.1 mL Ellman's reagent added, the absorbance was read within 5 min, at 412 nm against a sample blank (19).

Zn⁺² and Cu⁺² in serum and tissue

The sample of tissues were first heated in an oven set at 100-105 °C to an accurate weight. An exact amount of tissue (0.2 g) was then digested with 1mL of concentrated nitric acid in a polypropylene tube in an oven adjusted at 65°C for 2 hrs. Samples were diluted in distilledwater and measured with Perkin Elmer Analyst 800 atomic absorption spectrometer. The hollow cathod lamps of the respectives elements were operated under standart conditions using their respective resonance lines for Zn⁺² at 213.9 nm, for Cu⁺² at 324.8 nm. Samples were volatilized in an air acetylene flame, and the concentration of metal was read directly in micrograms per milliliter (µg/mL) after calibration of the scale with appropriate standards for zinc analysis 0.25-1.5 µg/mL of zinc standard solution, for copper analysis 1-5 µg/mL of copper standard solution. Distilled-deionized water (AAS grade) was used for the preparation of dilutions and standards of the trace element analysis. Results were expressed as micrograms per gram (µg/g) of dried tissue weight (20, 21).

Statistical analysis of data

Data obtained from animal experiments were expressed as the mean standard error (± SEM). Statistical differences between the treated and the control groups were evaluated by ANOVA and Students-Newman-Keuls post-hoc tests. P < 0.05 was considered to be significant [*p < 0.05; ** p < 0.01; *** p < 0.001]. Histopathologic data were considered to be nonparametric; therefore, no statistical tests were performed.

RESULTS AND DISCUSSION

In Turkish folk medicine, the aerial parts of *P. lanceolata* have been used as anti-inflammatory, antimicrobial, diuretic and antiasthmatic agent. It has also been reported to possess wound healing and analgesic potential when applied topically (22).

The present study was designed to evaluate wound healing activity potential of the aqueous and methanol extracts of *P. lanceolata*. For this purpose linear incision and circular excision wound models were employed on the experimental animals. According to the results obtained from linear incision wound model aqueous extract exerted significant activity with

Table 1. Effect of the extracts from *Plantago lanceolata* on linear incision wound model

Material	Statistical Mean \pm SEM	(Tensile strength %)
Vehicle	9.94 \pm 2.13	4.52
Negative control	9.51 \pm 2.02	-
Aqueous extract	14.82 \pm 1.17	49.09***
MeOH extract	11.03 \pm 1.97	10.97
Madecassol [®]	15.58 \pm 0.92	56.74***

*** : p < 0.001; SEM: Standard error of the mean

Percentage of tensile strength values: Vehicle group was compared to Negative control group; Extracts were compared to Vehicle group

Table 2. Effect of the extracts from *Plantago lanceolata* on circular excision wound model

Material	Wound area \pm SEM (Contraction %)						
	0	2	4	6	8	10	12
Vehicle	18.13 \pm 2.02	17.96 \pm 1.94	16.03 \pm 1.81 (5.26)	14.25 \pm 1.72	8.56 \pm 1.39 (11.70)	4.33 \pm 0.98 (14.59)	3.82 \pm 0.70 (7.06)
Negative control	17.92 \pm 2.14	17.13 \pm 2.07	16.92 \pm 1.97	13.71 \pm 1.53	9.68 \pm 1.76	5.07 \pm 1.02	4.11 \pm 0.93
Aqueous extract	18.06 \pm 2.29	17.01 \pm 2.02 (5.29)	13.24 \pm 1.90 (17.40)	9.46 \pm 1.52 (33.61)*	5.58 \pm 1.33 (34.81)**	2.04 \pm 0.80 (52.89)***	0.57 \pm 0.44 (85.08)***
MeOH extract	19.23 \pm 2.76	18.13 \pm 2.57	15.90 \pm 2.14 (0.81)	12.83 \pm 2.09 (19.96)	7.35 \pm 2.67 (14.14)	3.91 \pm 1.75 (9.69)	2.85 \pm 1.09 (25.39)
Madecassol [®]	18.77 \pm 2.06	16.03 \pm 1.75 (10.75)	12.74 \pm 1.54 (20.52)	8.45 \pm 0.76 (40.70)**	4.02 \pm 0.69 (53.04)**	1.14 \pm 0.31 (73.67)***	0.00 \pm 0.00 (100.00)***

*: p < 0.05; **: p < 0.01; *** : p < 0.001; SEM: Standard error of the mean

Percentage of contraction values: Vehicle group was compared to Negative control group; Extracts were compared to Vehicle group

the tensile strength value of 49.09% (Table 1). Similarly, the aqueous extract showed 85.08% (p<0.001) contraction value in circular excision wound model (Table 2).

According to the histopathological analysis, proper healing, particularly, re-epithelization was detected in the reference group, followingly in the aqueous and methanol extract groups. On the other hand, re-epithelization was not completed in the vehicle and negative control groups (Table 3). Histopathological results are supported with figures (Figure 1) which stained with HE and VG.

High collagen concentration in the wound area is an important parameter, shows the strength of

the healed tissue (23). Therefore, the HP level of the tissues were assessed for the determination of the collagen level. Both extract demonstrated significant increase in HP content, but the level determined for the aqueous extract treated tissues was much higher than that of the tissues treated with methanol extract (44.27 and 29.84 μ g/mg respectively) (Table 4).

For the deremintaion of anti-inflammatory activity of *P. lanceolata*, Whittle Method, based on the inhibition of acetic acid induced increase in capillary permeability, was used. Both extract showed significant and moderate anti-inflammatory activity at 200 mg/kg dose (Table 5).

Free radicals play an important role in the pathogenesis of several diseases such as inflammation and cancer. Furthermore, fibroblasts and other cells may be killed by excess free radicals, especially the radical oxygen species and skin lipids will be made less flexible. Therefore, more recently, antioxidants have a widespread usage in the treatment of several diseases due to their radical scavenging effects (24, 25). In the present study the levels of

TBARS, GSH, TSH, HP and tissue trace elements were analysed. In the control group, increase in the level of TBARS and decrease in the level of GSH and TSH indicated incomplete healing (Table 6). On the other hand, aqueous and methanol extract groups demonstrated a complete healing by exerting similar activity results with the reference group.

Table 3. Wound healing processes and healing phases of the experimental group animals

Groups	Wound Healing Processes							Healing Phases			
	S	U	RE	FP	CD	MNC	PMN	NV	I	P	R
Vehicle	+	-	++	++/+++	++	++	+	++/+++	++	++/+++	++
Negative control	+/+	-	+/+	++/+++	++/+++	++	+/+	++/+++	++	++/+++	+/+
Aqueous extract	+	-	++	++	++	+/+	-/+	++	+/+	++	++
MeOH extract	+	-	++	++	++	++	+	++	++	++/+++	++
Madecassol®	+	-	+++	+/+	+/+	+	-	+	-/+	+/+	+++

*HE and VG stained sections were scored as mild (+), moderate (++) and severe (+++) for epidermal and/or dermal re-modeling. S: Scab, U: Ulcus, RE: Re-epithelization, FP: Fibroblast proliferation, CD: Collagen depositions, MNC: Mononuclear cells, PMN: Polymorphonuclear cells, NV: Neovascularization, I: Inflammation phase, P: Proliferation phase, R: Re-modeling phase.

Table 4. Effects of the test ointments prepared from the extracts of *Plantago lanceolata* on hydroxyproline content

Material	Hydroxyproline ($\mu\text{g}/\text{mg}$) \pm SEM
Vehicle	14.12 \pm 1.92
Negative control	12.71 \pm 1.58
Aqueous extract	44.27 \pm 1.13***
MeOH extract	29.84 \pm 1.70*
Madecassol®	55.08 \pm 0.69***

* : p < 0.05; *** : p < 0.001 significant from the control; SEM: Standard error of the mean

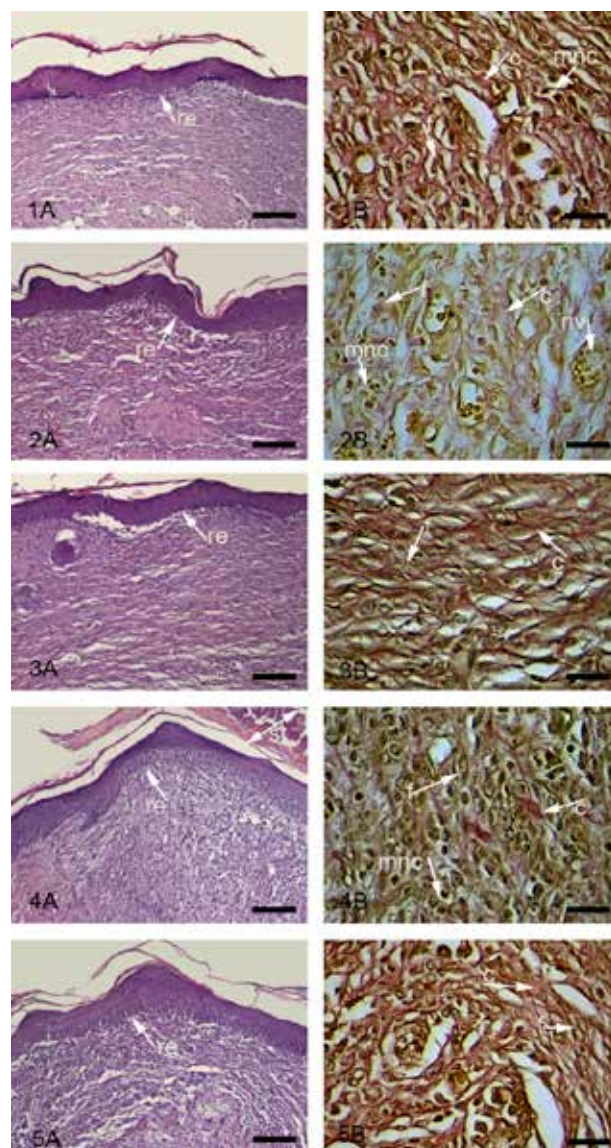


Figure 1. Histopathological view of wound healing and epidermal/dermal re-modeling in the vehicle, negative control, extract ointments and Madecassol[®] administered animals.

Skin sections show the hematoxylin & eosin (HE) stained epidermis and dermis in A, and the dermis stained with Van Gieson (VG) in B. The original magnification was x 100 and the scale bars represent 120 μm for figures in A, and the original magnification was x 400 and the scale bars represent 40 μm for B. Data are representative of 6 animal per group. 1) Vehicle; 2) Negative Control; 3) Aqueous extract 4) Methanol extract 5) Reference

Trace elements play an important role in the several biological processes. Enhancement of these elements in the tissue or blood serum was shown to have preventive effects against some diseases. For instance, zinc and copper have role in metabolic and biochemical processes in the healing phase of remodeling (26, 27). The results of the present study showed that the

serum zinc levels in the test and reference groups were higher than that of the control group. However, there was not much difference for tissue Zn^{+2} levels between the groups tested. This could be probably due to the migration of the trace elements to the wound area. The aqueous extract treated tissue was found to have high level of Cu^{+2} , while the level of copper in

the serum was determined to be significantly reduced (Table 7). This outcome was supported by the results of a previous study by Bang et al.

Moreover, *P. lanceolata* was shown to have *in vitro* inhibitory effect on the production of nitric oxide (NO) (4). The *P. lanceolata* ointment

Table 5. Inhibitory effect of the extracts from *Plantago lanceolata* on acetic acid-induced increase in capillary permeability

Material	Dose (mg/kg)	Evans blue concentration (Lg/mL) ± SEM	Inhibition (%)
Control		9.62 ± 0.74	
Aqueous extract	100	8.13 ± 0.45	15.49
	200	7.02 ± 0.53	27.03*
MeOH extract	100	8.71 ± 0.33	9.46
	200	7.24 ± 0.71	24.74*
Indomethacin	10	4.78 ± 0.27	50.31***

*: p<0.05. ***: p<0.001 significant from the control; SEM: Standard error of the mean

Table 6. TBARS, GSH and TSH levels in rat tissues

Material	Mean ± SD		
	TBARS (nmol/g)	GSH (µmol/g)	TSH (µmol/g)
Control	215.9 ± 13.2	4.7 ± 0.8	9.7 ± 0.8
Vehicle	198.3 ± 9.1*	4.9 ± 1.0	8.9 ± 0.6
Aqueous extract	161.5 ± 9.7***	7.0 ± 0.9**	11.9 ± 0.9***
MeOH extract	161.9 ± 14.4***	6.8 ± 1.1**	11.6 ± 1.7***
Reference	142.4 ± 7.2***	5.2 ± 0.4	8.7 ± 0.8

*: p < 0.05; ** : p < 0.01; *** : p < 0.001 significant from the control; SD: Standard deviation

Table 7. Zn⁺² and Cu⁺² levels in serum and tissue

Material	Mean ± SD			
	Serum		Tissue	
	Zn ⁺² (mg/L)	Cu ⁺² (mg/L)	Zn ⁺² (mg/L)	Cu ⁺² (mg/L)
Control	0.897 ± 0.95	0.599 ± 0.05	6.096 ± 0.29	300.35 ± 15.0
Vehicle	0.942 ± 0.04	0.628 ± 0.05	6.400 ± 0.26	291.18 ± 7.29
Aqueous extract	1.193 ± 0.07**	0.415 ± 0.07***	5.999 ± 0.43	318.3 ± 13.35**
MeOH extract	1.174 ± 0.07***	0.558 ± 0.05	6.842 ± 0.47	347.98 ± 11.43***
Reference	1.289 ± 0.18***	0.655 ± 0.08	6.656 ± 0.37	371.86 ± 9.19***

** : p < 0.01; *** : p < 0.001 significant from the control; SD: Standard deviation

(2002), which stated the high transfer of Cu⁺² to wound area (26).

Previous studies revealed that *Plantago* species possess wide range of biological activities such as cytotoxic, anti-inflammatory, antioxidant, and antispasmodic (4, 5, 7). The extracts obtained from *P. lanceolata* exerted antiphlogistic effect on the carrageenan-induced edema (28, 29).

accelerated the process of tendon healing by faster regaining of the original diameter. The activity was attributed to its anti-inflammatory properties owing to acteoside, a phenylethanoid, which inhibits arachidonic acid in the cyclooxygenase pathway (6). More recently, Oloumi et al. demonstrated the significant healing effect of the water-soluble extract of *P.*

lanceolata ointment on experimental collagenase-induced tendinitis in burros.

The polysaccharide type components were determined to activate the macrophages and therefore, stimulate TNF- α production (30). The phytochemical studies on the *Plantago* species demonstrated that these species are rich in iridoids such as catalpol, aucubin and asperuloside; and flavonoids such as apigenin-7-O-glucoside and scutellarein (3, 4). Especially, flavonoids are important secondary metabolites having potent antioxidant effects (4, 7). Previous reports have revealed the antioxidant and cytoprotective effects of the phenolic and flavonoid type compounds isolated from the aqueous and methanol extract of *P. lanceolata* (4). Therefore, the antioxidant and wound healing potential of the aqueous extract of *P. lanceolata* reported in the present study could be attributed to the flavonoids and phenolic components. In addition, it can also be assumed that the synergistic effect of both anti-inflammatory and antioxidant activity accelerated the wound healing process.

CONCLUSION

The results of the present study showed the remarkable antioxidant and wound healing activities of the aqueous extract of *P. lanceolata* which could be due to the presence of phenolic compounds.

ACKNOWLEDGEMENT

This study was supported by İnönü University Scientific Research Council (Project No: 2012/40).

REFERENCES

1. Adetutu A, Morgan WA, Corcoran O, Ethnopharmacological survey and *in vitro* evaluation of wound-healing plants used in South-western Nigeria, J Ethnopharmacol 137, 50-56, 2011.
2. Brown KL, Phillips TJ, Nutrition and wound healing, Clin Dermatol 28, 432-439, 2010.
3. Fons F, Gargadennec A, Gueiffier A, Roussel JL, Andary C, Effects of cinnamic acid on polyphenol production in *Plantago lanceolata*, Phytochemistry 49, 697-702, 1998.
4. Beara IN, Lesjak MM, Orcic DZ, Simin ND, Simin DC, Bozin BN, Dukic NMM, Comparative analysis of phenolic profile, antioxidant, antiinflammatory and cytotoxic activity of two closely-related Plantain species: *Plantago altissima* L. and *Plantago lanceolata* L., Food Sci Technol 47, 64-70, 2012.
5. Harput US, Genc Y, Saracoglu I, Cytotoxic and antioxidative activities of *Plantago lagopus* L. and characterization of its bioactive compounds, Food Chem Toxicol 50, 1554-1559, 2012.
6. Oloumi MM, Vosough D, Derakhshanfar A, Nematollahi MH, The healing potential of *Plantago lanceolata* ointment on collagenase-induced tendinitis in burros (*Equus asinus*), J Equine Vet Sci 30, 1-5, 2011.
7. Gálvez M, Cordero CM, Lázaro ML, Cortés F, Ayuso MJ, Cytotoxic effect of *Plantago* spp. on cancer cell lines, J Ethnopharmacol 88, 125-130, 2003.
8. Çavdar C, Sifil A, Çamsarı T, Reaktif oksijen türleri ve antioksidan savunma, Türk Nefroloji Diyaliz ve Transplantasyon Dergisi 3, 92-95, 1997.
9. Peşin Süntar I, Küpeli Akkol E, Yılmaz D, Baykal T, Kırmızıbekmez H, Alper M, Yeşilada E, Investigations on the *in vivo* wound healing potential of *Hypericum perforatum* L., J Ethnopharmacol 127, 468-477, 2010.
10. Suguna L, Singh S, Sivakumar P, Sampath P, Chandrakasan G, Influence of *Terminalia chebula* on dermal wound healing in rats, Phytoter Res 16, 227-231, 2002.
11. Lodhi S, Pawar RS, Jain AP, Singhai AK, Wound healing potential of *Tephrosia purpurea* (Linn.) Pers. in rats, J Ethnopharmacol 108, 204-210, 2006.
12. Süntar I, Baldemir A, Coşkun M, Keleş H, Küpeli Akkol E, Wound healing acceleration effect of endemic *Ononis* species growing in Turkey, J Ethnopharmacol 135, 63-70, 2011.
13. Süntar I, Küpeli Akkol E, Keles H, Yesilada E, Sarker SD, Arroo R, Baykal T, Efficacy of *Daphne oleoides* subsp. *oleoides* used for wound healing: Identification of the active compounds through bioassay guided isolation technique, J Ethnopharmacol 141, 1058-1070, 2012.
14. Degim Z, Çelebi N, Sayan H, Babül A, Erdoğan D, Take G, An investigation on skin wound healing in mice with a taurine-chitosan gel formulation, Amino Acids 22, 187-198, 2002.
15. Whittle BA, The use of changes in capillary permeability in mice to distinguish between narcotic and non-narcotic analgesics, Brit J Pharmacol 22, 246-253, 1964.

16. Yesilada E, Küpeli E, *Clematis vitalba* L. aerial part exhibits potent anti-inflammatory, antinociceptive and antipyretic effects, *J Ethnopharmacol* 110, 504-515, 2007.
17. Ohkawa H, Ohishi N, Yagi K, Assay for lipid peroxides in animal tissues by thiobarbituric acid reaction, *Anal Biochem* 95, 351-358, 1979.
18. Jamall IS, Smith JC, Effects of cadmium on glutathione peroxidase, superoxide dismutase and lipid peroxidation in the rat heart: A possible mechanism of cadmium cardiotoxicity, *Toxicol Appl Pharmacol* 80, 33-42, 1985.
19. Sedlak J, Lindsay RH, Estimation of total protein-bound and nonprotein sulfhydryl groups in tissue with Ellman's reagent, *Anal Biochem* 25, 192-205, 1968.
20. Friel JK, Ngyuen CD, Dry and wet ashing techniques compared in analyses for zinc, copper, manganese and iron in hair, *Clin Chem* 32(5), 739-742, 1986.
21. Luterotti S, Zanic-Grubisic T, Juretic D, Rapid and simple method for the determination of copper, manganese and zinc in rat liver by direct flame atomic absorption spectrometry, *Analyst* 117, 141-144, 1992.
22. Samuelsen AB, The traditional uses, chemical constituents and biological activities of *Plantago major* L., *J Ethnopharmacol* 71, 1-21, 2000.
23. Alves CC, Torrinhas RS, Giorgi R, Brentani MM, Logullo AF, Arias V, Mauad T, Silva LFF, Waitzberg L, Short-term specialized enteral diet fails to attenuate malnutrition impairment of experimental open wound acute healing, *Nutrition* 26, 873-879, 2010.
24. Reuter S, Gupta SC, Chaturvedi MM, Aggarwal BB, Oxidative stress, inflammation and cancer: How are they linked?, *Free Radi Bio Med* 49(11), 1603-1616, 2010.
25. Bharathi RV, Kumudha Veni B, Suseela JL, Thirumal M, Antioxidant and wound healing studies on different extracts of *Stereospermum colais* leaf, *Int J Res Pharm Sci* 1(4), 435-439, 2010.
26. Bang RL, Bader AL, Sharma PN, Mattapallil AB, Behbehani A, Dashti H, Trace elements content in serum, normal skin and scar tissues of keloid and normal scar patients, *J Trace Elem Exp Med* 15, 57-66, 2002.
27. Berger MM, Shenkin A, Trace element requirements in critically ill burned patients, *J Trace Elem Med Bio* 21, 44-48, 2007.
28. Beara IN, Orcic DZ, Lesjak MM, Dukic NM, Pekovic BA, Popovic MR, Liquid chromatography/tandem mass spectrometry study of anti-inflammatory activity of Plantain (*Plantago L.*) species, *J Pharmaceut Biomed* 52, 701-706, 2010.
29. Darrow K, Bowers MD, Phenological and population variation in iridoid glycosides of *Plantago lanceolata* (Plantaginaceae), *Biochem Syst Ecol* 25, 1-11, 1997.
30. Biringaninea G, Vrayb B, Vercruysseb V, Vanhaelen-Fastréa R, Vanhaelena M, Dueza P, Polysaccharides extracted from the leaves of *Plantago palmata* Hook. f. induce nitric oxide and tumor necrosis factor- α production by interferon- γ -activated macrophages, *Nitric Oxide* 12, 1-8, 2005.

Received: 06.08.2015

Accepted: 24.12.2015